

Enucleation of a Cystic Lesion in Mandible Associated with Oxygen Therapy and Bone Grafting: Case Report

Jeferson Luis de Oliveira Stroparo^{1,2}, Geraldo Fernando Stroparo², Allan Fernando Giovanini¹, Flares Baratto-Filho^{3,4}, Shaban Mirco Burgoa La Forcada⁵, Marilisa Carneiro Leão Gabardo^{1*} and Tatiana Miranda Deliberador⁶

¹School of Health Sciences, Universidade Positivo, Curitiba, Paraná, Brazil

²Private Practice, Irati, Paraná, Brazil

³Department of Dentistry, Universidade Tuiuti do Paraná, Curitiba, Paraná, Brazil

⁴Departament of Dentistry, Universidade da Região de Joinville, Joinville, Santa Catarina, Brazil

⁵Instituto Odontológico das Américas, Curitiba, Paraná, Brazil

⁶Faculdade ILAPEO, Curitiba, Paraná, Brazil

***Corresponding Author:** Marilisa Carneiro Leão Gabardo, Escola de Ciências da Saúde, Universidade Positivo, Curitiba, Paraná, Brazil.

Received: July 21, 2021; **Published:** August 30, 2021

DOI: 10.31080/ecde.2021.20.01725

Abstract

Introduction: Dentists often face intraosseous cystic lesions in their clinical activity and for the solution of these cases they need to include surgical and non-surgical treatments, a decision that will depend on the analysis of the lesion and the possible prognosis.

Objective: Report an enucleation of a cystic lesion in the mandible, in the chin region, associated with oxygen therapy and bone grafting.

Case Report: A male patient, 69 years old, came to the dental office complaining of a sensation of swelling in the chin region, just below the mandibular incisors. At clinical examination, a bulging in the anterior region was observed. The tomographic examination revealed a periapical lesion with defined limits, circumscribed and associated with the region of teeth 41, 42 and 32. Endodontic treatment of these teeth was performed followed by enucleation surgery. In which a half-moon incision was made, with total flap detachment. The area was accessed and the lesion was removed. The site was mechanical and then chemically decontaminated with tetracycline hydrochloride and saline solution, followed by application of active oxygen-based gel (blue@m). Then bone grafting with Nanosynt® synthetic biomaterial was performed. Histopathological examination showed that it was a chronic inflammatory repair process in periodontal ligament tissue, corresponding to a cystic lesion in the late stage of healing. The panoramic radiography, in three months after the operation, showed absence of lesions, indicating the success of the procedure.

Conclusion: In cases of large radiographic findings, the treatment must be careful enucleation of the lesion followed by mechanical and chemical decontamination, as well as histopathological examination to confirm the diagnosis and to discard possible signs of malignancy. It can also be noted that oxygenotherapy favours the healing, improving the success of the cases.

Keywords: Bone Cysts; Bone Grafting; Enucleation Surgery; Histology; Oxygen Therapy

Abbreviation

CT: Computed Tomography

Introduction

The pathogenesis of pulp necrosis may be associated with several causes, such as tooth decay, restorations, irritating factors, and trauma [1]. Once the microorganisms contaminate the root canal system, the spread of the infectious process can extend to the periarticular region and thus generate lesions [1].

Among the morbidities that affect the periapical tissues are the so-called intraosseous cystic lesions, which are characterized by bone demineralization, bone rarefaction or remodeling [2]. The most common types of radiolucent lesions are apical granulomas and cysts, which may represent around 73% of these findings, although there are other diagnostic possibilities, such as keratocyst tumors, giant cell lesions and ameloblastomas [3,4].

For the preoperative evaluation of this pathology, panoramic radiographs and computed tomography (CT) can be used [5], while the treatment can be surgical or not, which will depend mainly on the size of the lesion and its possible prognosis [4].

Among the surgical interventions, enucleation is an option when it is aimed the preservation of the affected teeth [6]. It is known that during the procedure an adequate mechanical and chemical decontamination of the area where the lesion was removed is necessary [7]. Thus, oxygen therapy can be used to help local healing, as Imano., *et al.* (2019) and Stroparo., *et al.* (2021) suggested, once it improves healing, stimulates angiogenesis in surgical sites, and also due to the antimicrobial effect [8,9].

Aim of the Study

The aim of this study was to report the enucleation of a cystic lesion in the mandible, in which was associated oxygen therapy and bone grafting.

Case Report

A male patient, 69 years old, came to the dental office complaining of a sensation of swelling in the chin region, just below the mandibular incisors.

At clinical examination, a bulging in the anterior region was observed. The tomographic exam revealed a periapical lesion with defined limits, circumscribed and associated with the region of teeth 41, 42 and 32 (Figure 1A and 1B). The pulp sensitivity test was performed (Endo Ice Spray, Maquira, Maringá, PR, Brazil), confirming a negative response. The diagnostic hypothesis was a cystic lesion. Then Amoxicillin 500 mg (one capsule every eight hours) was prescribed for seven days. The endodontic treatment of the teeth was carried out two weeks before the surgery.

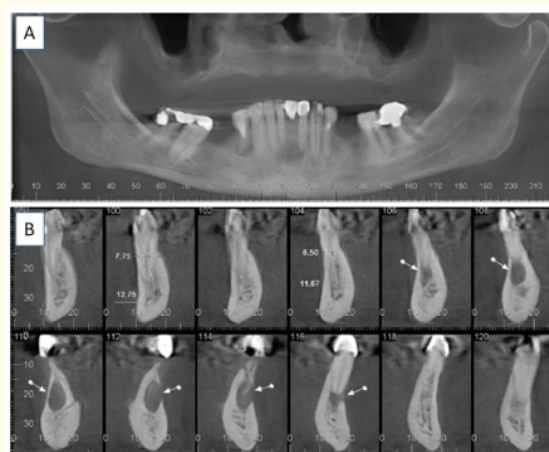


Figure 1: A) Panoramic CT image showing the lesion in the mandibular incisor region; B) CT sections 106 to 116 showing the dimensions of the lesion.

On the day of the surgical procedure, the patient had a blood pressure of 120/80 mmHg, 80 BPM, 18 breaths per minute.

Extra and intraoral antisepsis was performed with 0.12% chlorhexidine digluconate. For left and right mental nerve anesthesia, a tube of 4% articaine hydrochloride plus 1:100,000 epinephrine was used (Articaine, DFL, Rio de Janeiro, RJ, Brazil).

As the lesion was below the mandibular incisors (Figure 2A), a half-moon incision was made and a total flap detachment was performed with a Molt periosteal elevator (Figure 2B). The area was accessed and the lesion was removed with hemostatic forceps (Figure 2C). Then, curettage was performed with a Lucas curette and lime (Quinelato, Rio Claro, São Paulo, Brazil). The site was irrigated with tetracycline hydrochloride solution plus saline solution during five minutes to promote good chemical decontamination (Figure 2D). Additionally, active oxygen-based gel (blue[®]m, 5 PillarsResearch B.V., Netherlands) was used for two minutes to aid in decontamination and healing (Figure 2E).

Finally, a 0.5g fine-grained synthetic biomaterial Nanosynt[®] graft was inserted (FGM, Joinville, SC, Brazil) (Figure 2F). Simple sutures were performed (Figure 2G).

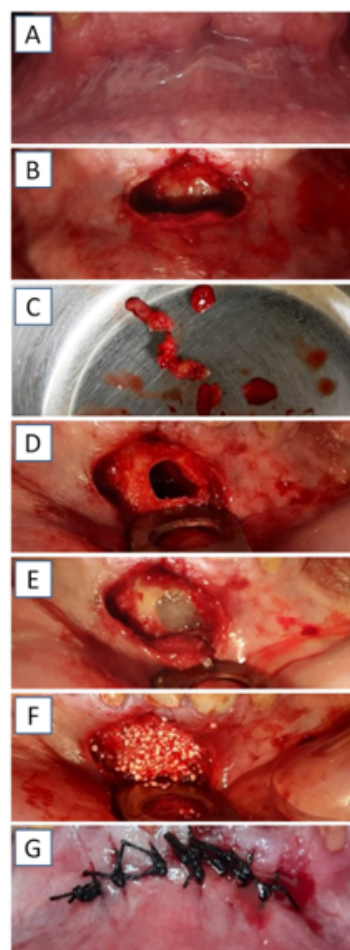


Figure 2: A) Initial image; B) Half-moon incision; C) Lesion removed; D) Area of the lesion being decontaminated; E) Complementation of decontamination with active oxygen-based gel; F) Synthetic biomaterial graft; G) Simple suture.

Amoxicillin 500 mg (one every eight hours) was prescribed for seven days, Ibuprofen 600 mg (one every eight hours) for three days and Paracetamol 750 mg (one every eight hours) for three days.

The material was sent for histopathological analysis. On macroscopic examination, the fragments of the lesion measured, together, about 10 x 0.8 x 0.3 cm. The tissue was brownish and stretchy. Upon microscopic examination, it was noted that the tissues were of fibrous connective tissue, exhibiting reparative fibroplasty and vascular neoformation, with edema and diffuse lymphocytic inflammatory infiltrate, which extended to the trabecular alveolar bone. There was presence of hemosiderophages and gigantocellular reaction. No residual epithelial cystic lining elements were identified, and there were no signs of malignancy either (Figure 3).

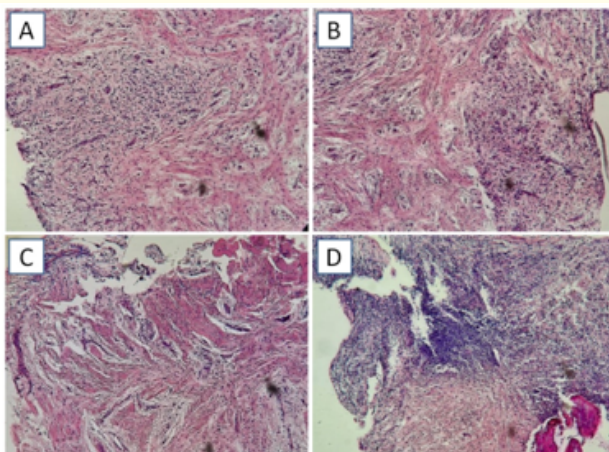


Figure 3: All images show fragments of unmodeled dense connective tissue, exhibiting fibroplasia and fusiform cell content, with areas of vascular neoformation (angiogenesis). Amidst the fibroplastic tissue, there is a moderate chronic inflammatory process, represented by a predominantly lympho-plasmocytic infiltrate, discrete giant Langhans cells, and bone mineral remnant, completing the histopathological picture. Diagnostic - nonspecific chronic inflammatory process (dental granuloma).

The diagnosis of the lesion showed that it was a chronic inflammatory repair process in periodontal ligament tissue, which may correspond to a cystic lesion in a late stage of healing.

The patient reported that he did not feel any symptoms or discomfort after the procedure. In the panoramic radiography three months after the surgery, the absence of a lesion can be observed, showing the success (Figure 4).

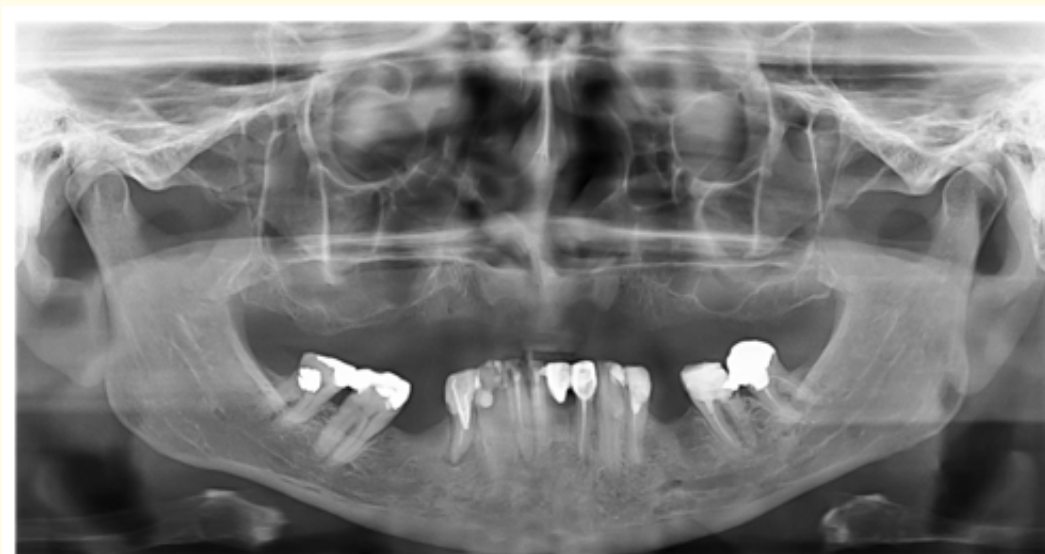

Figure 4: Three-month postoperative period, with no lesion.

Discussion

In this case report, the procedure for enucleation of a cystic lesion associated with correct chemical decontamination associated with oxygen therapy was described, which prepared the area for bone grafting, resulting in success according to the postoperative evaluation after three months.

To aid in the diagnosis, it was decided to ask the patient to undergo a CT exam. According to Hoshi, *et al.* (2018), for oral surgery, this exam offers a three-dimensional assessment, which favors the analysis of the dimensions of the lesion and its relationship with other oral structures [5].

According to Martins, *et al.* (2015), for pathologies that resemble cysts, there are two possibilities of treatment, surgical and surgical; the latter is indicated for benign conditions, pathologies with small dimensions and with a good prognosis [4]. However, Martins, *et al.* (2015) and Hoshi, *et al.* (2018), mention that for large ones, radiolucent lesions that resemble keratosis, giant cell lesions or other hypotheses that may be malignant, surgical enucleation is recommended. Furthermore, these lesions can cause bone and root resorptions and paresthesia [10]. Therefore, the decision, together with the patient, was to undergo surgical intervention.

During the procedure, the use of active oxygen-based gel was an option based on the findings of Imano, *et al.* (2019) and Stroparo, *et al.* 2021, which reported that oxygen therapy makes healing faster, as the active release of oxygen promotes an antibacterial effect and also has an angiogenic stimulus, with a better prognosis for the cases [8,9].

As for the histopathological examination, Servato, *et al.* (2013), reinforce the need for the procedure for all periapical enucleated lesions, as the clinical diagnosis can fail and thus generate an incorrect diagnosis. All cysts that develop in the anterior region of the mandible must be carefully analyzed in order to exclude the presence of an orthokeratinized odontogenic cyst or keratocystic odontogenic tumor, as they behave more aggressively [11].

Conclusion

It is concluded that enucleation of the lesion, with mechanical decontamination associated with oxygen therapy, prior to bone grafting, favored the present case, with a sign of success three months after the surgery.

Conflict of Interest

There are no conflicts of interest.

Bibliography

1. López-Marcos Joaquín F. "Aetiology, classification and pathogenesis of pulp and periapical disease". *Medicina Oral, Patología Oral y Cirugía Bucal* 9 (2004): 58-62.
2. Mosier Kristine M. "Lesions of the Jaw". *Seminars in Ultrasound, CT, and MR* 36.5 (2015): 444-450.
3. Koivisto Tyler, *et al.* "Frequency and distribution of radiolucent jaw lesions: a retrospective analysis of 9,723 cases". *Journal of Endodontics* 38.6 (2012): 729-732.
4. Martins Jorge NH., *et al.* "Very Large Inflammatory Odontogenic Cyst with Origin on a Single Long Time Traumatized Lower Incisor". *Journal of Clinical and Diagnostic Research: JCDR* 9.7 (2015): ZD07-10.
5. Hoshi Reiko, *et al.* "Preoperative imaging findings as predictors of postoperative inferior alveolar nerve injury following mandibular cyst surgery". *Journal of Oral Science* 60.4 (2018): 618-625.

6. Stroparo Jeferson LO., *et al.* "Apicectomy associada à regeneração óssea guiada: relato de caso". *RSBO* 18.1 (2021): 115-120.
7. Blahuta R and P Stanko. "Root-end resection". *Bratislavské Lekárske Listy* 113.4 (2012): 240-242.
8. Imano MH., *et al.* "Uso do Gel de Oxigênio como Otimizador da Cicatrização Tecidual em Áreas Doadoras e Receptoras na Técnica de Enxerto Gengival Livre. *IMPLANT NEWS PERIO* 1.1 (2019).
9. Stroparo Jeferson LO., *et al.* "Application of an Active Oxygen (blue[®]m) With Free Connective Graft Technique for Root Coverage – a Case Report". *Research, Society and Development* 10.5 (2021): e57510515468.
10. Madras Jonathan and Henry Lapointe. "Keratocystic odontogenic tumour: reclassification of the odontogenic keratocyst from cyst to tumour". *Journal Canadian Dental Association* 74.2 (2008): 165-165.
11. Silva Servato João Paulo., *et al.* "Orthokeratinized odontogenic cysts presenting as a periapical lesion: report of a case and literature review". *Journal of Endodontics* 40.3 (2014): 455-458.

Volume 20 Issue 9 September 2021

©All rights reserved by Jeferson Luis de Oliveira Stroparo., *et al.*